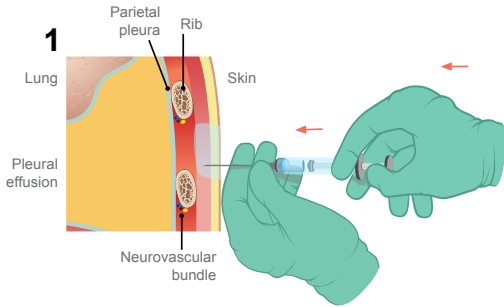
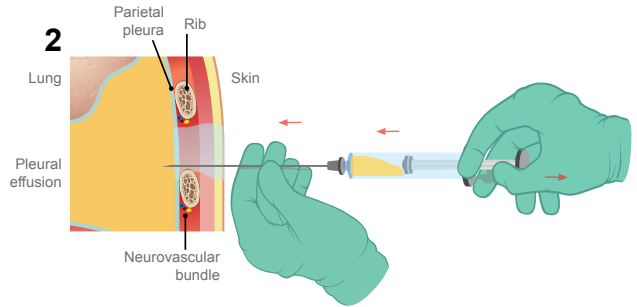


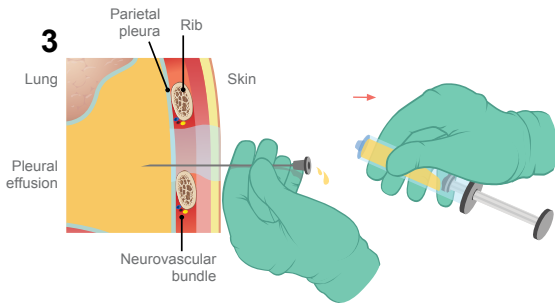
# NEEDLE THORACENTESIS



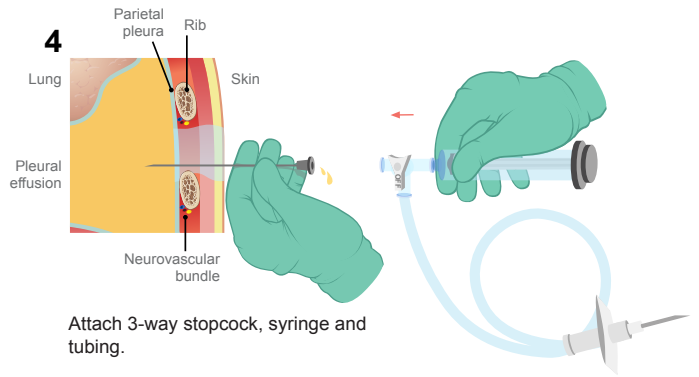
Local anesthetic is used. Note that the needle should not be advanced beyond the distance from the skin to the chest cavity as demonstrated on ultrasound.



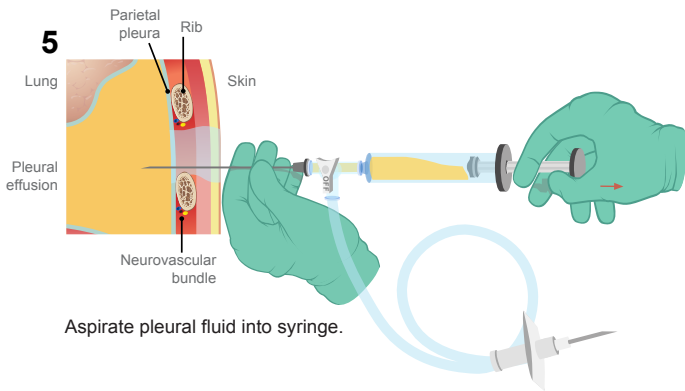
Insert needle while simultaneously aspirating on syringe. Note the needle should not be advanced more than the distance to the pleural fluid as demonstrated on ultrasound.



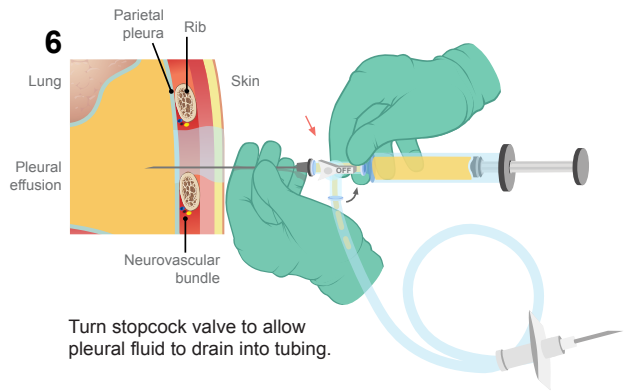
Remove syringe.



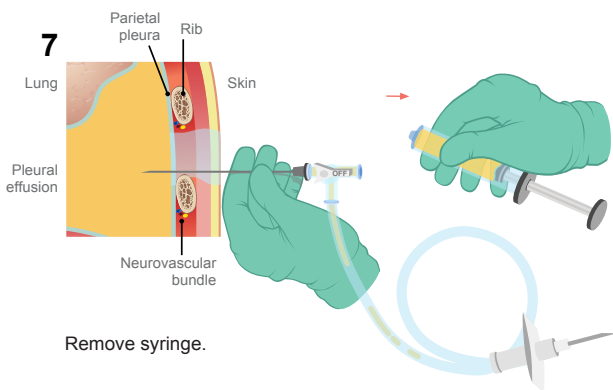
Attach 3-way stopcock, syringe and tubing.



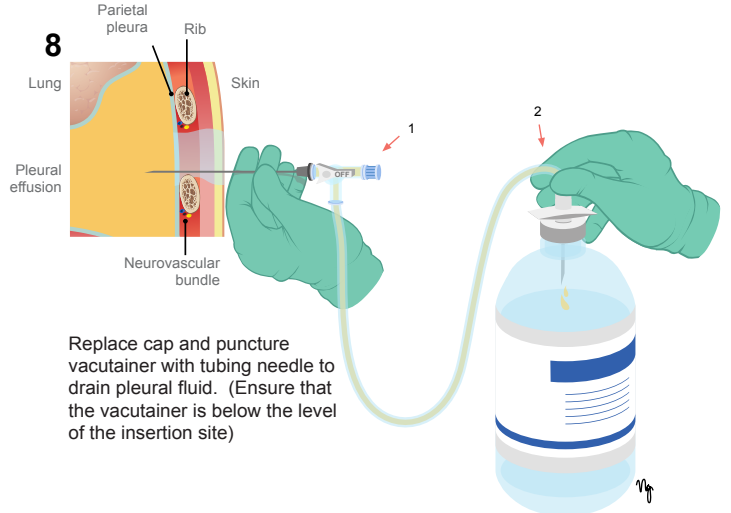
Aspirate pleural fluid into syringe.



Turn stopcock valve to allow pleural fluid to drain into tubing.



Remove syringe.



Replace cap and puncture vacutainer with tubing needle to drain pleural fluid. (Ensure that the vacutainer is below the level of the insertion site)